

A CASE OF POSTERIOR SCLERITIS WITH EXUDATIVE RETINAL DETACHMENT

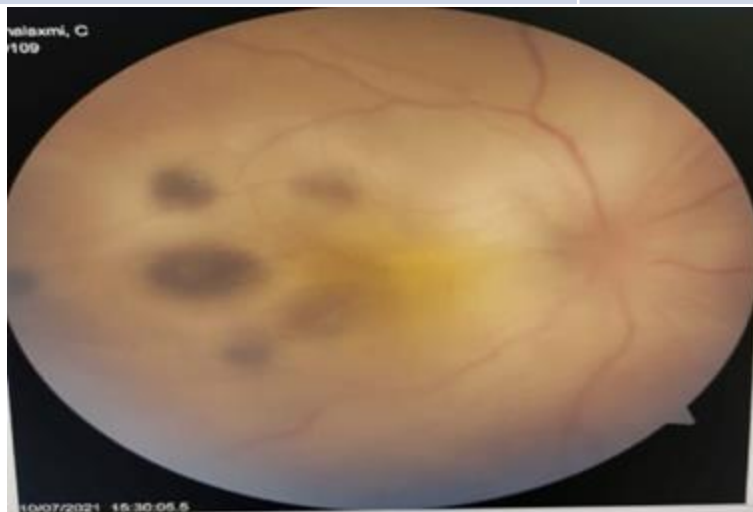Author: Dr. Afrin Neeha

Co-Author: Dr. A. Divya

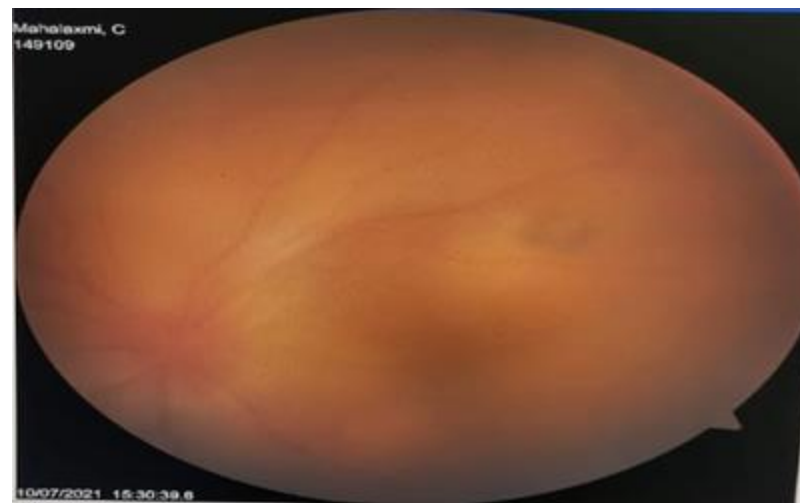
- A 37 years old female came with chief complaints of diminution of vision in both eyes since 10 days
- Associated with pain and redness since 10 days
- No H/o HTN,DM,
- No H/o trauma
- Similar complaints 6 months back undergone treatment and improved.
- On examination

	RIGHT EYE	LEFT EYE
UCVA	PL+	6/60
BCVA	PL+	6/60
IOP	18mm of Hg	11mm of Hg
ANTERIOR SEGMENT	PIGMENTS ON BACK OF CORNEA, AC CELLS 2+	PIGMENTS ON BACK OF CORNEA ,AC-CELLS 2+,SYNECHIAE
PUPIL	SLUGGISHLY REACTING	ACTIVE
LENS	IMSC	CLEAR

	RIGHT EYE	LEFT EYE
B SCAN	CHOROIDAL THICKENING , T SIGN	CHOROIDAL THICKENING , T SIGN
FUNDUS	EXUDATIVE RD ,OLD RETINAL SCARS	OLD RETINAL SCAR, EXUDATIVE RD WITH SUB RETINAL FLUID
FFA	PIN POINT LEAKS IN POST POLE	PIN POINT LEAKS IN POST POLE



FUNDUS PHOTO OF RE SHOWING SRF MULTIPLE POCKETS IN POSTERIOR POLE WITH EXUDATIVE RD ,OLD MULTIPLE SCARS NOTED



FUNDUS PHOTO OF LE : SRF MULTIPLE POCKETS IN POSTERIOR POLE WITH EXUDATIVE RD

- **Investigations :**

- Toxoplasma - IgG , IgM negative
- Montoux test- induration of 18mm is noted after 48hrs.
- ESR 15mm/hr,
- PMN-77,
- Lymphocytes-18
- TB Gold Interferon Gamma Release Assay-Negative.

- **PROVISIONAL DIAGNOSIS :**

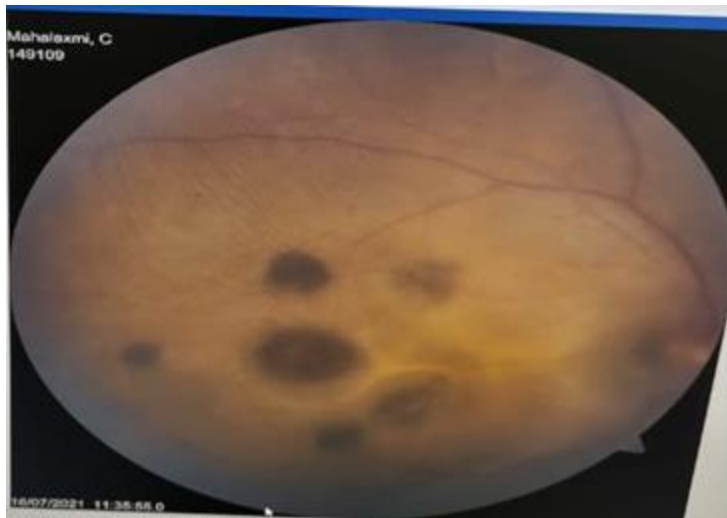
- Both Eyes Posterior scleritis with exudative RD was made based on clinical findings and investigations.

- **TREATMENT :**

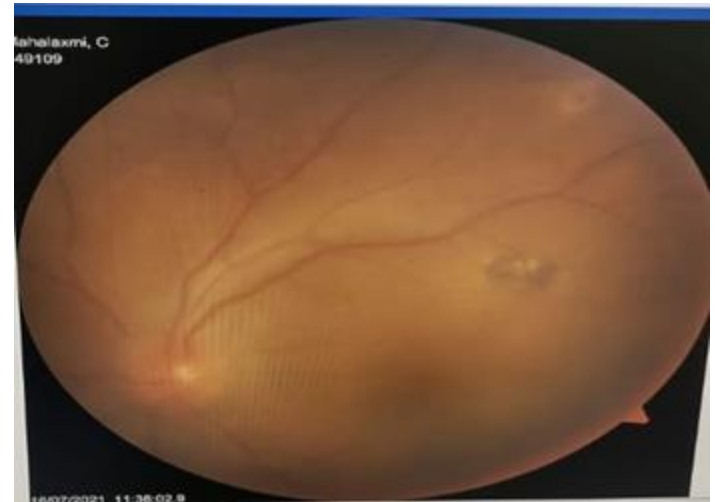- IV methyprednisalone for 3days, followed by oral prednisolone in tapering dose for 6wks,
- Prednisalone eye drops tapered over 6 wks,
- Homatropine eye drops 3 times per day for 3wks,
- Atropine eye ointment b/d for 3wks

Next visit

	RIGHT EYE	LEFT EYE
After 6 days	CF 1 METER	6/12
After 6 weeks	6/12	6/9



FUNDUS PHOTO OF RE AFTER 6 DAYS
: REDUCED SRF AND DECREASED
EXUDATIVE RD



FUNDUS PHOTO OF LE AFTER 6
DAYS : RESOLVED SRF POCKETS